

Indian J Ophthalmol. 2015 Feb; 63(2): 146–151.

PMCID: PMC4399124

doi: [10.4103/0301-4738.154392](https://doi.org/10.4103/0301-4738.154392)

Chromatic-achromatic perimetry in four clinic cases: Glaucoma and diabetes

[Inmaculada Cabezos](#), [Maria José Luque](#),¹ [Dolores de Fez](#), [Vicenta Moncho](#), and [Vicente Camps](#)

Department of Optics, Pharmacology and Anatomy, University of Alicante, Alicante, Spain

¹Department of Optics, University of València, València, Spain

Correspondence to: Dr. Dolores de Fez, Department of Optics, Pharmacology and Anatomy, Carretera San Vicente del Raspeig s/n - 03690 San Vicente del Raspeig, Alicante, Spain. E-mail: dolores.fez@ua.es

Received 2014 Oct 8; Accepted 2015 Feb 27.

Copyright : © Indian Journal of Ophthalmology

This is an open-access article distributed under the terms of the Creative Commons Attribution-Noncommercial-Share Alike 3.0 Unported, which permits unrestricted use, distribution, and reproduction in any medium, provided the original work is properly cited.

Abstract

Background:

Some diseases that affect the visual system may show loss of chromatic-achromatic sensitivity before obvious physical signs appear in the usual examination of the eye's posterior segment. A perimetric study has been conducted with four typical patients with glaucoma and diabetes, at different stages of the disease.

Materials and Methods:

In addition to the standard white-on-white (standard automated perimetry [SAP]), a test battery has been used to study patient's contrast sensitivity, using stimuli with different chromatic, spatial, and temporal content (multichannel perimetry). The choice of stimuli tries to maximize the response of different visual mechanisms: Achromatic (parvocellular and magnocellular origin); chromatic red-green (parvocellular origin); and chromatic blue-yellow (koniocellular origin).

Results:

The results seem to indicate losses in the achromatic-parvocellular perimetry and both chromatic perimetry tests, undetected by conventional SAP.

Conclusions:

Our results illustrate that our patients without visible retinal alterations show signs of suspicion in multichannel perimetry.

Keywords: Achromatic perimetry, chromatic perimetry, diabetes, glaucoma, konio, magno, parvo

Color perimetry has interesting clinical application for the diagnosis and detection of certain eye conditions, due to the variations that certain diseases can cause in chromatic thresholds, both in the red-green (RG) and the blue-yellow (BY) pathways.[1,2,3,4]

The separate study of the visual function of both the chromatic and achromatic mechanisms could be more efficient in detecting sensitivity variations, and such variations would not be obscured by the intrusion of other mechanisms. Currently, the supply of conventional perimeters that are capable of performing a chromatic perimetry test is very limited and with reduced options regarding the possibility of choosing the physical characteristics of the stimulus (see Monhart[5] for a review of the available techniques).

For the study that we have carried out, we have used a multichannel perimetric technique, which provides the user with the choice of a wide range of characteristics of the stimulus, such as chromaticity, spatial and temporal frequency, size, duration or border smoothing.[6,7] It allows measurements of contrast sensitivity in different directions of the color space and with stimuli with different space-time features with a dual objective: to determine in which pathway the losses are greater and to maximize the probability of detecting these losses by modifying the detectability of the stimuli by means of their spatiotemporal frequency content. This procedure has the additional advantage of yielding results that can readily be compared between stimuli, since the task performed by the observer is always the same.

With this technique, we hope to detect early functional losses, before clinical signs are observable or in the asymptomatic stages, which with conventional perimetry testing could still go unnoticed. The interpretation of the results would be much easier if we could ensure that in each stimuli used we are isolating a particular visual mechanism. Unfortunately, although selected stimuli particularly favor a single mechanism, we cannot be sure of silencing the rest. Mechanism isolation would improve the ability to detect loss of functionality of the visual system, according to previous results[8,9,10,11] and this is the motivation behind different lines of research based in the multichannel perimetry technique used in this paper.

Focusing in this type of the perimetric test, our aim is to illustrate how different perimetric techniques contribute to gain a clearer picture of the functional losses experienced by a given patient. To this end, we show four illustrative cases of two pathologies affecting the visual system (glaucoma and diabetes), at two stages of the evolution of the disease (patients with and without obvious clinical signs).

Materials and Methods

Four patients, two diabetic (D1 and D2) and two glaucomatous (G1 and G2) subjects, selected for routine visits at our University Clinic, participated in the study. Labels 1 and 2 indicate the progress of the pathology, with "1" to indicate an incipient state, with no obvious signs in the retina in a basic ophthalmological exploration, and "2" to indicate a more advanced state. The study adheres to the tenets of the Declaration of Helsinki for Research Involving Human Observers.

The patients underwent the following test battery: measurement of visual acuity (VA) with the best visual correction, air tonometry (TOPCON CT-80, from Topcon Europe Medical B.V. Capelle a/d IJssel, Netherlands), exploration of the anterior segment (TOPCON IS-600) and of the posterior segment (TOPCON TRC-NW6S Nonmydriatic Retinal Camera and OPTOPOL SOCT Copernicus HR, from OPTOPOL Technology Sp. Zawiercie, Poland), study of papillary reaction and symmetry, detection of alterations of color vision (Farnsworth-Munsell [FM]-100 Hue test, X-Rite Europe GmbH, Regensburg, Suiza), SAP test (SBP-3000 TOPCON) and the multichannel perimetry tests.

In the FM-100 Hue test, the total error score (TES) values and the total partial error scores values for the RG and BY color axes were calculated. These results were compared to typical values corresponding to the age range of the patient.[12]

For the conventional SAP, we used the fast threshold strategy, with the default parameters (size III stimuli, 0.2 s presentation time and 0.6 s interval time, in an area of 30°). Two global parameters describe overall sensitivity loss and inhomogeneity in the visual field: The mean defect (MD') and the loss variance (LV). MD' is defined as the mean difference in sensitivity between the standard and the subject, which differs in

sign from the equivalent parameter used in the multichannel perimeter. The symbol (') has been introduced to mark this difference.

Multichannel perimeter

This multichannel perimetry technique has already been used in previous studies.[8,9,10,11] The reader is referred to the paper by Antón *et al.*[11] for a thorough explanation of all the details of the device, stimulus characteristics and measurement method.

In our study, the device evaluates the detection thresholds for spatiotemporal patterns in a 60° horizontal field by 40° vertical field, centered on the fovea, at a viewing distance of 25 cm. 5° stimulus size, 1 s maximum presentation time, and 0.5 s maximum, random time interval. Testing points were uniformly distributed in a 6 × 4 grid covering the visual field, plus a point at the fovea. The measures were carried out in a dark room, by a staircase procedure. The complete session never exceeded 1 h.

Stimuli can be modulated along the achromatic (A), RG and BY direction of the opponent modulation space. The spatial and temporal frequency of the pattern can be chosen to favor a particular postreceptoral mechanism (see Merigan and Maunsell[13] and Dacey,[14] but take into account the objections by Swanson *et al.*[15]). Along the achromatic axis two stimuli are used: One stimulus of low spatial frequency (0.5 cpd) and high temporal frequency (12 Hz), favoring the magnocellular pathway (i.e. A-0.5/12), and one medium spatial frequency (4 cpd) and low temporal frequency (2 Hz), favoring the parvocellular pathway (A-4/2).[13] The chromatic RG and BY axes were evaluated with low spatial (0.5 cpd) and temporal (2 Hz) frequency stimuli.[13] The chromatic properties of these stimuli should favor the parvo and koniocellular pathways, respectively.

Two global parameters have been used: The MD, or mean deviation, defined as the mean of the differences between patient and standard observer at each point of the visual field, and the pattern standard deviation (PSD), defined as the standard deviation of these differences.

Results

We present in the following sub-sections first the results in the preliminary optometric and ophthalmological exam of the patients, including the results of the FM-100 hue test, and then a global description of the results obtained in the different perimetry tests.

Optometric and ophthalmological exam

Patient D1

A 35-year-old woman with type-1 insulin-dependent diabetes mellitus of some 20 years of evolution. The left eye was examined. The basic ophthalmic exploration data are within normal limits (VA, tonometry, anterior/posterior segment) [Fig. 1a]. The subject shows normal color discrimination with the FM-100 Hue test, although the RG partial score is larger than for the normal average subject.

Patient D2

A 31-year-old man with type-1 insulin-dependent diabetes mellitus of some 20 years of evolution, diagnosed with nonproliferative diabetic retinopathy. The right eye was examined. VA, tonometry, and the exploration of anterior segment are within the normal limits. However, numerous scattered microaneurysms and hard exudates can be observed in the exploration of the posterior segment [Fig. 1b]. The macula does not present signs of edema, and preserves its structure (hard exudates appear close by, but they do not protrude into it). Furthermore, pinpoint hemorrhages can be seen. The patient has not been treated with photocoagulation, but small deposits associated with cholesterol were found in his retina. With the FM-100 hue test, the patient has normal color discrimination, with the RG partial score greater than for the normal average subject.

Although this patient regularly underwent medical revisions and was monitored by an endocrinologist, who prescribed the insulin treatment, his first visit to an ophthalmologist dated from 2 years before this study, when serious loss of visual function was apparent in almost all the optometric tests.

Patient G1

A 53-year-old woman who, during routine revisions, presents intraocular pressure values between 20 and 24 mmHg and a high pachymetric value (580 μm). The left eye was examined. The basic ophthalmic exploration data are within normal limits (VA, tonometry, anterior/posterior segment) [Fig. 1c]. The subject shows normal color discrimination.

Patient G2

A 49-year-old woman, who had been diagnosed with chronic glaucoma a year prior to the study, undergoing antihypertensive therapy in both eyes. The right eye was examined. The basic ophthalmic exploration data are within normal limits (VA, tonometry, anterior segment). However, typical ocular signs of glaucoma could be observed in the fundus image obtained by retinography [Fig. 1d]: The papilla was excavated (with an approximate ratio of 7/10) and the “bayonet sign” could be seen in some of the emerging vessels of the papilla.

The TES is outside the 95% confidence interval of the normal sample in the same age range ($P < 0.05$), and color discrimination is low both along the RG and the BY axes.

Perimetry tests

The total deviation and pattern deviation maps for each of the perimetry tests used and each patient can be seen in Figs. 2–5. The global parameters of each perimetry have been presented in Table 1. Analysis of the results shows that the clinical manifestations presented by the two diabetes and two glaucoma patients have not been the same in all tests studied. Patients labeled “1” to indicate an incipient state (D1 and G1), that do not show obvious physical signs in optical coherence tomography (OCT) or fundus eye, have obtained normal results both on the FM-100 Hue test and in SAP. With the multichannel perimeter, the mean sensitivity of the patient may even be better than the average normal subject, except with the Ap tests (for which sensitivity is worse than average, although remaining within normal limits) [Table 1], in BY perimetry for D1 (which shows significant loss) and some points with significant absolute and relative losses in the chromatic channels for G1. Patients labeled “2” to indicate a more advanced state (D2 and G2), yield significant signs of pathology with all perimetric tests and retinography [Figs. 3 and 5], but both have normal OCT, and only G2 has a nonnormal result on the FM test.

In both diabetic patients, the MD value indicates a significant pathological result for the BY stimulus [Table 1], in agreement with the literature.[16,17,18,19] In addition, the D2 patient has a significant absolute sensitivity loss and abnormal visual field irregularity only in the two achromatic stimuli [Fig. 3]. In the rest of the tests, in spite of the presence of abnormal points in the visual field, the global parameters remain within normal limits.

In the G1 patient, MD values are normal in both chromatic perimetric tests, but RG shows more points with relative sensitivity losses [Fig. 4], in agreement with the literature that shows that this mechanism is usually selectively affected by this pathology.[20,21,22,23,24,25,26,27,28,29] With the G2 patient, all perimetric tests exhibit significant losses in MD and the shape of the visual field is also abnormal [Fig. 5].

For all patients in the study, we can highlight a common behavior in the MD values obtained for the Ap stimulus, that indicate sensitivity values below the average normal subject, even when the subject is above average with other tests, although MD is outside normal limits only in the patients D2 and G2.

The results of perimetric testing derived by the multichannel perimeter have been compared with the

results obtained with conventional achromatic SAP, already validated and used in routine clinical practice. The areas of loss of sensitivity obtained from the two different techniques are not always the same, except at the points of greatest loss of sensitivity, where both techniques match. The results in the chromatic (RG for G1, BY for D1) and achromatic perimetry tests of parvocellular origin (G1 and D1) show that losses of sensitivity were detected which were not revealed by SAP.

Discussion

It would seem that for the two patients without eye fundus damage, D1 and G1, more information was obtained from the chromatic mechanisms than from studying sensitivity using conventional achromatic perimetry. The two patients in the advanced stage of the pathology (D2 and G2), were used to check that the technique did detect serious loss of visual function. The contributions of the technique to the knowledge of the visual system of the patients have two aspects: In the first place, to determine what visual mechanisms, if any, are more impaired at a given point of the pathology, and in the second place to search for stimuli that would help to monitor the progression of the pathology. The comparative study of the four tested visual mechanisms might allow a more complete analysis of the effects of the pathology and the treatments the patient is receiving, and this we hope may help to minimize their adverse effects. At present, this is a work in progress.

However, we have to be careful when making this kind of statements about the usefulness of different diagnosis techniques. In the literature, there is no agreement as to the evidence that some techniques are more sensitive than others. There are works that show that measurements that favor the magno[30,31,32] or the koniocellular[30,31] mechanisms may be more sensitive for the early detection of pathologies than SAP. However, other studies have found similar glaucoma detection capabilities with SAP, short wavelength automated perimetry,[33,34] frequency doubling technology.[33,34,35] A given disease does not usually affect a single cell type, so a patient can be diagnosed with a particular technique and yet to appear as normal with another. However, although it seems unlikely that a single technique may be found that is sensitive and specific for an entire particular pathological population,[36] it is nonetheless important not to miss an early sign of functional loss. Combining different techniques instead of relying on a single test, although time-consuming, seems the only solution at present. For these two particular patients, relevant information would have been lost if only SAP had been performed. The difficulty lies in the possible low repeatability of the tests-see Monhart[5] for a review of standard techniques and de Fez *et al.*[7] for the repeatability of the multichannel perimeter-and in the reduced dynamic range for certain stimuli, particularly chromatic stimuli generated in a computer-controlled screen (again, see Monhart[5]).

We have shown that certain stimulus of the multichannel perimeter detects functional loss in subjects with glaucoma, optic nerve glaucoma suspects, and ocular hypertensive patients,[9] and that the technique yields repeatable results.[7] If we admit, therefore, that a multichannel perimetry technique could help in the possible early detection of the loss of functionality of the visual system, it would be appropriate to focus on what are the particular visual mechanisms more useful to study patients that still may not manifest loss with conventional perimeters and on the parameters of the stimuli that would be optimal for patient follow-up. We are still following this line of research with the purpose of analyzing a broader population that allows verification of the statistical significance.

Acknowledgments

The ATD multichannel perimeter was built thanks to the support of the Spanish Ministry for Science and Technology Grants DPI2000-0116-P4-02 and PTR 1995-0909-OP, in collaboration with INDUSTRIAS DE OPTICA SA (San Cugat del Vallés, Spain).

Footnotes

Source of Support: Nil.

Conflict of Interest: None declared.

References

1. Nomura R, Terasaki H, Hirose H, Miyake Y. Blue-on-yellow perimetry to evaluate S cone sensitivity in diabetics. *Ophthalmic Res.* 2000;32:69–72. [PubMed: 10754437]
2. O'Neill-Biba M, Sivaprasad S, Rodriguez-Carmona M, Wolf JE, Barbur JL. Loss of chromatic sensitivity in AMD and diabetes: A comparative study. *Ophthalmic Physiol Opt.* 2010;30:705–16. [PubMed: 20883358]
3. Castelo-Branco M, Faria P, Forjaz V, Kozak LR, Azevedo H. Simultaneous comparison of relative damage to chromatic pathways in ocular hypertension and glaucoma: Correlation with clinical measures. *Invest Ophthalmol Vis Sci.* 2004;45:499–505. [PubMed: 14744891]
4. McKendrick AM, Sampson GP, Walland MJ, Badcock DR. Contrast sensitivity changes due to glaucoma and normal aging: Low-spatial-frequency losses in both magnocellular and parvocellular pathways. *Invest Ophthalmol Vis Sci.* 2007;48:2115–22. [PubMed: 17460269]
5. Monhart M. What are the options of psychophysical approaches in glaucoma? *Surv Ophthalmol.* 2007;52(Suppl 2):S127–33. [PubMed: 17998037]
6. ATD Double Modulation Analyzer, Patent; US 7.641.344 B2 and 2246174 ES
7. de Fez D, Capilla P, Camps V, Luque MJ, Moncho V. Reliability in perimetric multichannel contrast sensitivity measurements. *Clin Exp Optom.* 2014;97:555–64. [PubMed: 25311660]
8. Morilla A, Antón A, Jiménez B, Rodríguez C, Martínez V, Fallon M, et al. ATD perimetry in glaucoma and ocular hypertensive patients. A preliminar study. *Acta Ophthalmologica Scandinavica.* 2007;85 doi: 10.1111/j.1600-0420.2007.01062_3373.x.
9. Morilla-Grasa A, Antón A, Santamaría S, Capilla P, Gómez-Chova J, Luque MJ, et al. Contrast sensitivity differences between glaucoma, ocular hypertensive and glaucoma suspect patients found by ATD perimetry, ARVO 2009. *Invest Ophthalmol Vis Sci.* 2009;50 E-Abstract 5290.
10. Díez-Ajenjo MA, Capilla P, Luque MJ. Red-green vs. blue-yellow spatio-temporal contrast sensitivity across the visual field. *J Mod Optic.* 2011;58:1736–48.
11. Antón A, Capilla P, Morilla-Grasa A, Luque MJ, Artigas JM, Felipe A. Multichannel functional testing in normal subjects, glaucoma suspects, and glaucoma patients. *Invest Ophthalmol Vis Sci.* 2012;53:8386–95. [PubMed: 23060138]
12. Kinnear PR, Sahraie A. New Farnsworth-Munsell 100 hue test norms of normal observers for each year of age 5-22 and for age decades 30-70. *Br J Ophthalmol.* 2002;86:1408–11. [PMCID: PMC1771429] [PubMed: 12446376]
13. Merigan WH, Maunsell JH. How parallel are the primate visual pathways? *Annu Rev Neurosci.* 1993;16:369–402. [PubMed: 8460898]
14. Dacey DM. Parallel pathways for spectral coding in primate retina. *Annu Rev Neurosci.* 2000;23:743–75. [PubMed: 10845080]
15. Swanson WH, Sun H, Lee BB, Cao D. Responses of primate retinal ganglion cells to perimetric stimuli. *Invest Ophthalmol Vis Sci.* 2011;52:764–71. [PMCID: PMC3053105] [PubMed: 20881286]
16. Davies N, Morland A. Extent of foveal tritanopia in diabetes mellitus. *Br J Ophthalmol.* 2003;87:742–6. [PMCID: PMC1771723] [PubMed: 12770973]

17. Scheffrin BE, Adams AJ, Werner JS. Anomalies Beyond sites of chromatic opponency contribute to sensitivity losses of an S-cone pathway in diabetes. *Clin Vision Sci.* 1991;6:219–28.
18. Tregear SJ, Knowles PJ, Ripley LG, Casswell AG. Chromatic-contrast threshold impairment in diabetes. *Eye (Lond)* 1997;11(Pt 4):537–46. [PubMed: 9425421]
19. Ong GL, Ripley LG, Newsom RS, Casswell AG. Assessment of colour vision as a screening test for sight threatening diabetic retinopathy before loss of vision. *Br J Ophthalmol.* 2003;87:747–52. [PMCID: PMC1771697] [PubMed: 12770974]
20. Kubová Z, Kuba M, Hrochová J, Sverák J. Motion-onset visual evoked potentials improve the diagnosis of glaucoma. *Doc Ophthalmol.* 1996;92:211–21. [PubMed: 9181348]
21. Klistorner AI, Graham SL. Early magnocellular loss in glaucoma demonstrated using the pseudorandomly stimulated flash visual evoked potential. *J Glaucoma.* 1999;8:140–8. [PubMed: 10209732]
22. Yücel YH, Zhang Q, Gupta N, Kaufman PL, Weinreb RN. Loss of neurons in magnocellular and parvocellular layers of the lateral geniculate nucleus in glaucoma. *Arch Ophthalmol.* 2000;118:378–84. [PubMed: 10721961]
23. Shabana N, Cornilleau Pérès V, Carkeet A, Chew PT. Motion perception in glaucoma patients: A review. *Surv Ophthalmol.* 2003;48:92–106. [PubMed: 12559330]
24. Jy-Haw Yu J, Kiyosawa M, Nemoto N, Momose K, Mori H, Mochizuki M. Correlation between frequency doubling technology perimetry and temporal frequency characteristics in early glaucoma. *Doc Ophthalmol.* 2003;107:93–9. [PubMed: 14661898]
25. Dimofte AD, Rusu V, Dimofte G. Changes in contrast sensitivity in glaucoma patients. *Oftalmologia.* 2004;48:72–6. [PubMed: 15598055]
26. McKendrick AM, Badcock DR, Morgan WH. Psychophysical measurement of neural adaptation abnormalities in magnocellular and parvocellular pathways in glaucoma. *Invest Ophthalmol Vis Sci.* 2004;45:1846–53. [PubMed: 15161849]
27. McKendrick AM, Badcock DR, Morgan WH. The detection of both global motion and global form is disrupted in glaucoma. *Invest Ophthalmol Vis Sci.* 2005;46:3693–701. [PubMed: 16186351]
28. Vaegan, Hollows FC. Visual-evoked response, pattern electroretinogram, and psychophysical magnocellular thresholds in glaucoma, optic atrophy, and dyslexia. *Optom Vis Sci.* 2006;83:486–98. [PubMed: 16840873]
29. Leeprechanon N, Giangiacomo A, Fontana H, Hoffman D, Caprioli J. Frequency-doubling perimetry: Comparison with standard automated perimetry to detect glaucoma. *Am J Ophthalmol.* 2007;143:263–71. [PubMed: 17178091]
30. Sample PA, Bosworth CF, Weinreb RN. Short-wavelength automated perimetry and motion automated perimetry in patients with glaucoma. *Arch Ophthalmol.* 1997;115:1129–33. [PubMed: 9298053]
31. Cellini M, Torreggiani A. Frequency doubling perimetry in ocular hypertension and chronic open angle glaucoma. *Acta Ophthalmol Scand Suppl.* 2002;236:24–5. [PubMed: 12390120]
32. Wu LL, Suzuki Y, Kunimatsu S, Araie M, Iwase A, Tomita G. Frequency doubling technology and confocal scanning ophthalmoscopic optic disc analysis in open-angle glaucoma with hemifield defects. *J Glaucoma.* 2001;10:256–60. [PubMed: 11558807]
33. Soliman MA, de Jong LA, Ismaeil AA, van den Berg TJ, de Smet MD. Standard achromatic perimetry,

short wavelength automated perimetry, and frequency doubling technology for detection of glaucoma damage. *Ophthalmology*. 2002;109:444–54. [PubMed: 11874745]

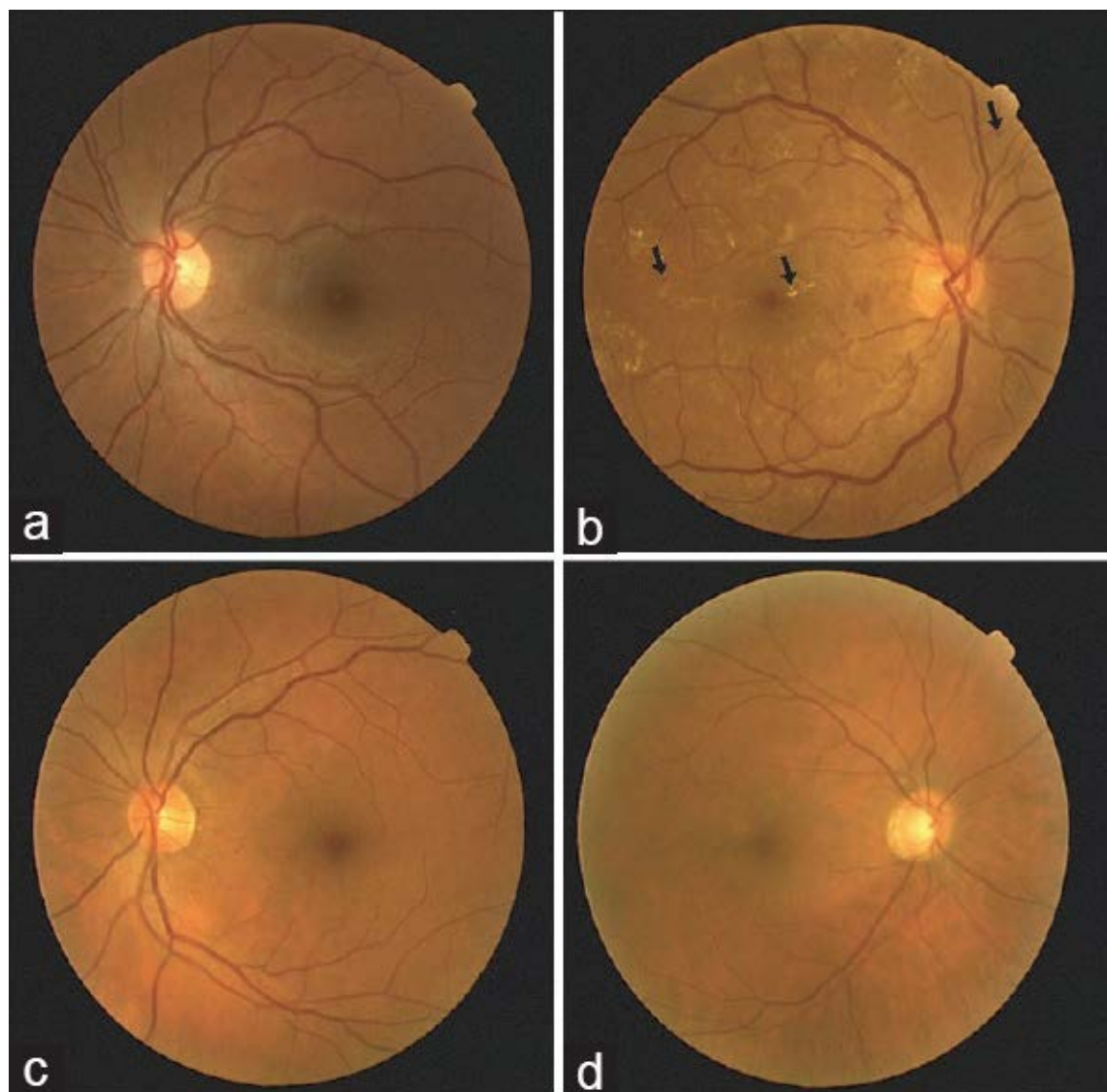
34. van der Schoot J, Reus NJ, Colen TP, Lemij HG. The ability of short-wavelength automated perimetry to predict conversion to glaucoma. *Ophthalmology*. 2010;117:30–4. [PubMed: 19896194]

35. Meyer JH, Funk J. High-pass resolution perimetry and light-sense perimetry in open-angle glaucoma. *Ger J Ophthalmol*. 1995;4:222–7. [PubMed: 7492934]

36. Sample PA, Medeiros FA, Racette L, Pascual JP, Boden C, Zangwill LM, et al. Identifying glaucomatous vision loss with visual-function-specific perimetry in the diagnostic innovations in glaucoma study. *Invest Ophthalmol Vis Sci*. 2006;47:3381–9. [PubMed: 16877406]

Figures and Tables

Figure 1



Retinography results for the four patients: (a) D1, (b) D2, (c) G1, (d) G2. The arrows signal the presence of scattered microaneurysms, hard exudates or pinpoint hemorrhages

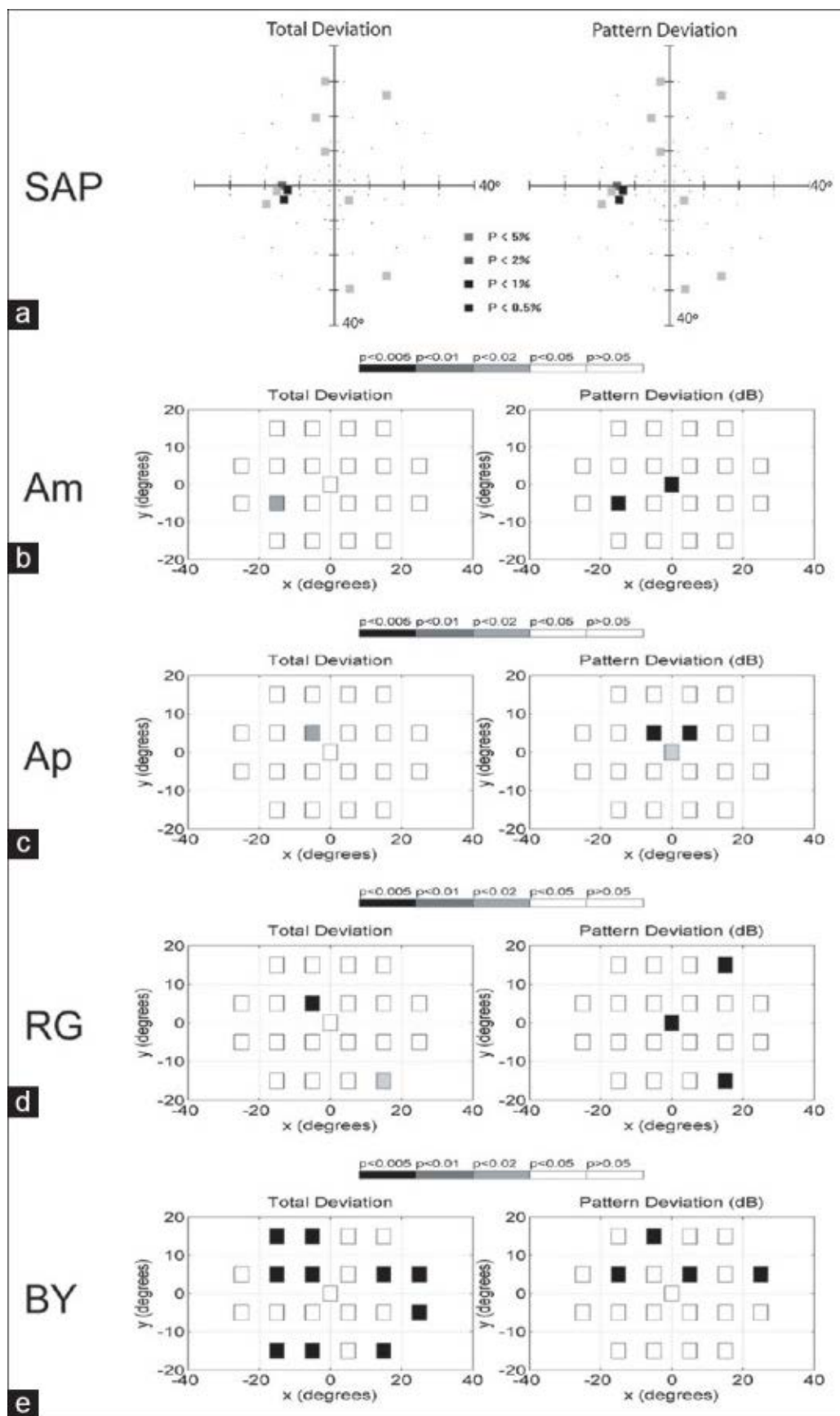
Table 1

	Patient D1	Patient D2	Patient G1	Patient G2
SAP				
MD'	-0.05	7.98	-0.64	7.61
LV	6.45	31.84 [^]	8.72	42.69 [^]
Am				
MD	1.13	-10.39*	1.19	-5.23*
PSD	1.59	2.80*	1.53	5.26*
Ap				
MD	-2.21	-3.52*	-0.66	-3.88*
PSD	2.84	3.46*	1.43	3.66*
RG				
MD	0.42	-0.48	0.46	-1.44*
PSD	1.61*	1.00	1.59	1.90*
BY				
MD	-1.87*	-5.67*	0.82	-3.99*
PSD	1.88	1.36	1.75	2.32*

*Corresponds to the values outside the 95% CI of the normal sample in the same age range, [^]Corresponds to LV values above the normal cut-off value (25 for this perimeter). MD': Mean defect, LV: Loss variance, SAP: Standard automated perimetry, MD: Mean deviation, PSD: Pattern standard deviation, Am: Achromatic magno, Ap: Achromatic parvo, RG: Red-green, BY: Blue-yellow, CI: Confidence interval

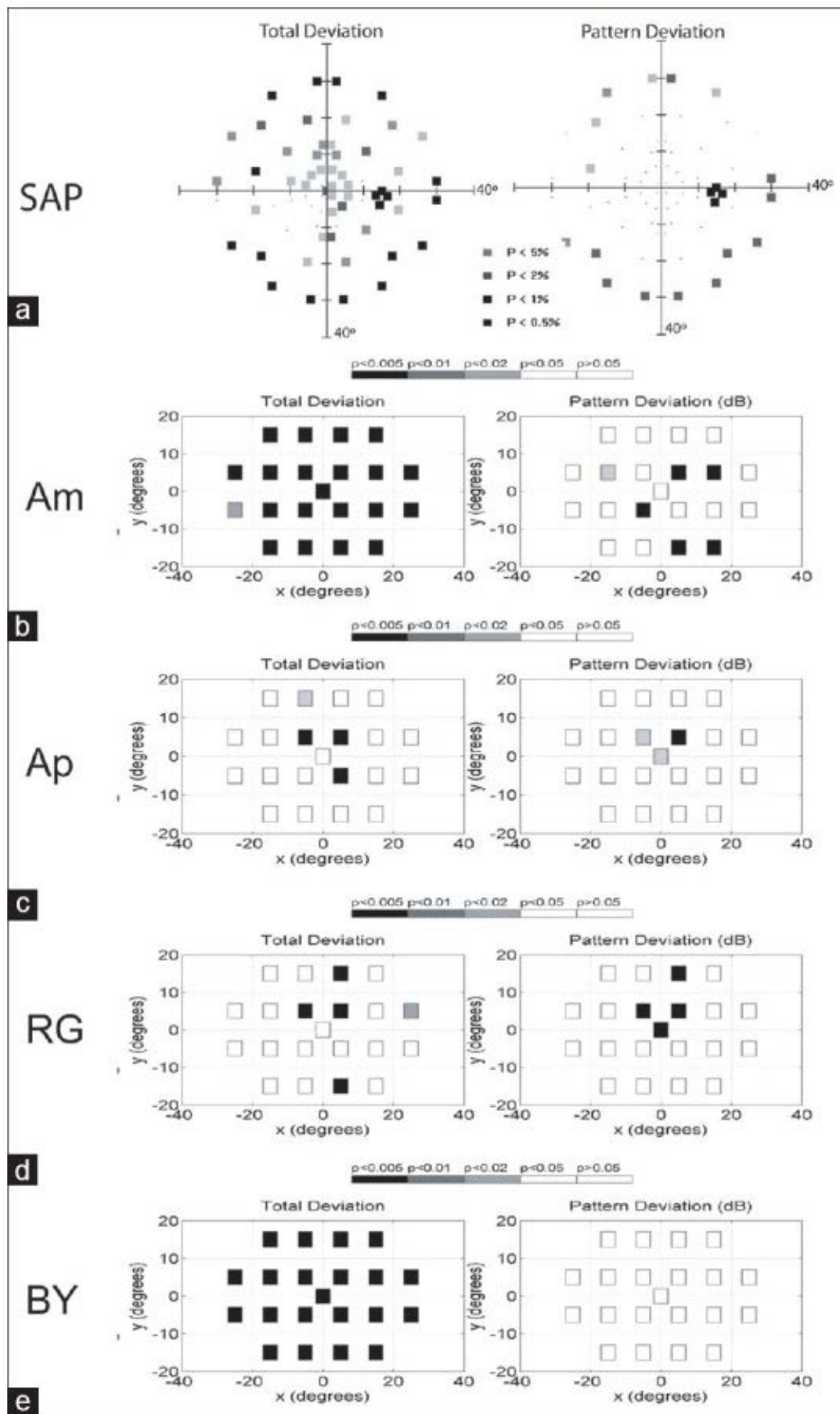
Global indexes for the different perimetric tests: MD' and LV values for SAP and MD and PSD for the four stimuli of multichannel perimetry, Am, Ap, RG, and BY

Figure 2



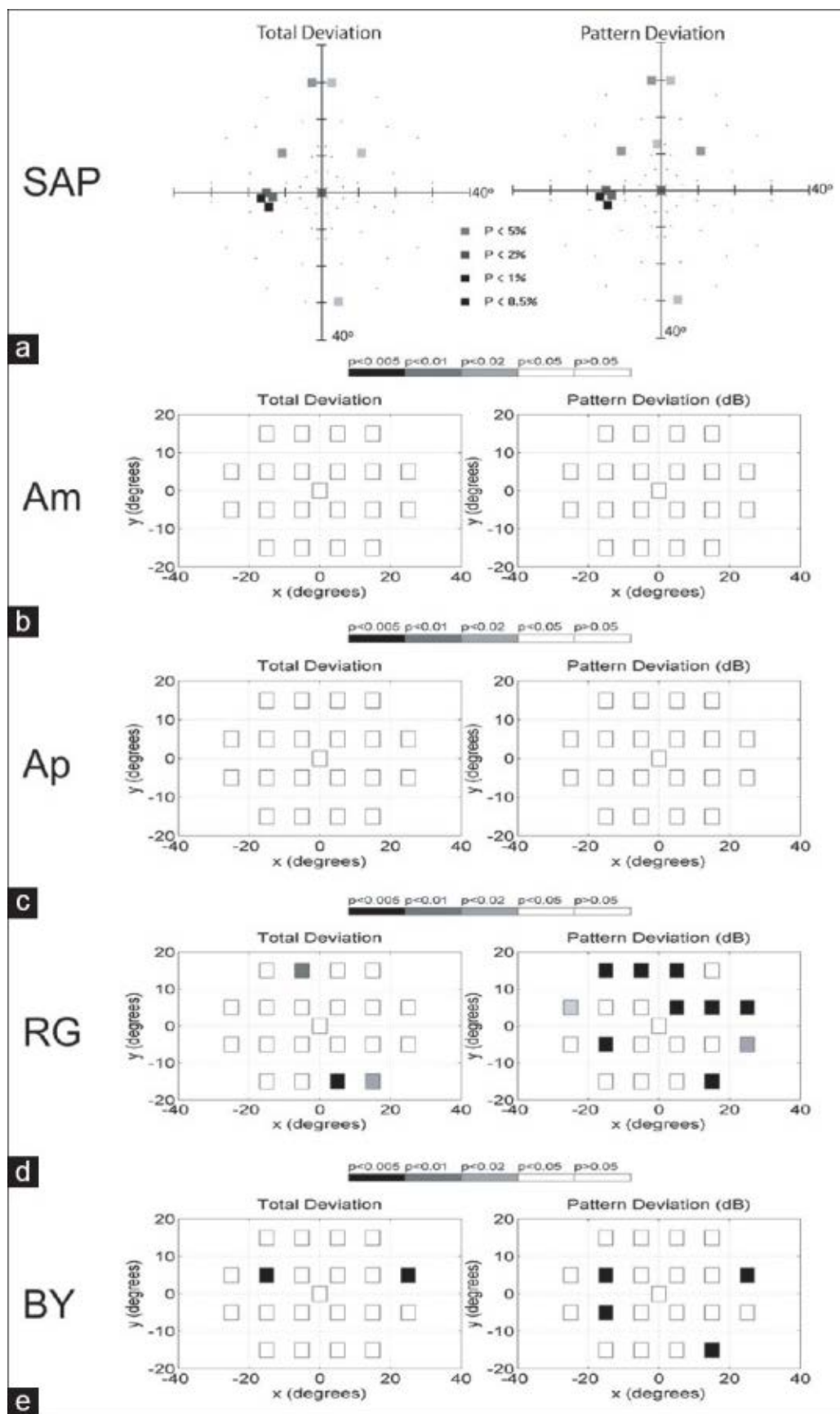
Results for patient D1, left: Total deviation map, right: Pattern deviation map. (a) static automated perimetry, (b-e) multichannel perimetry results with Am, Ap, RG and BY stimuli

Figure 3



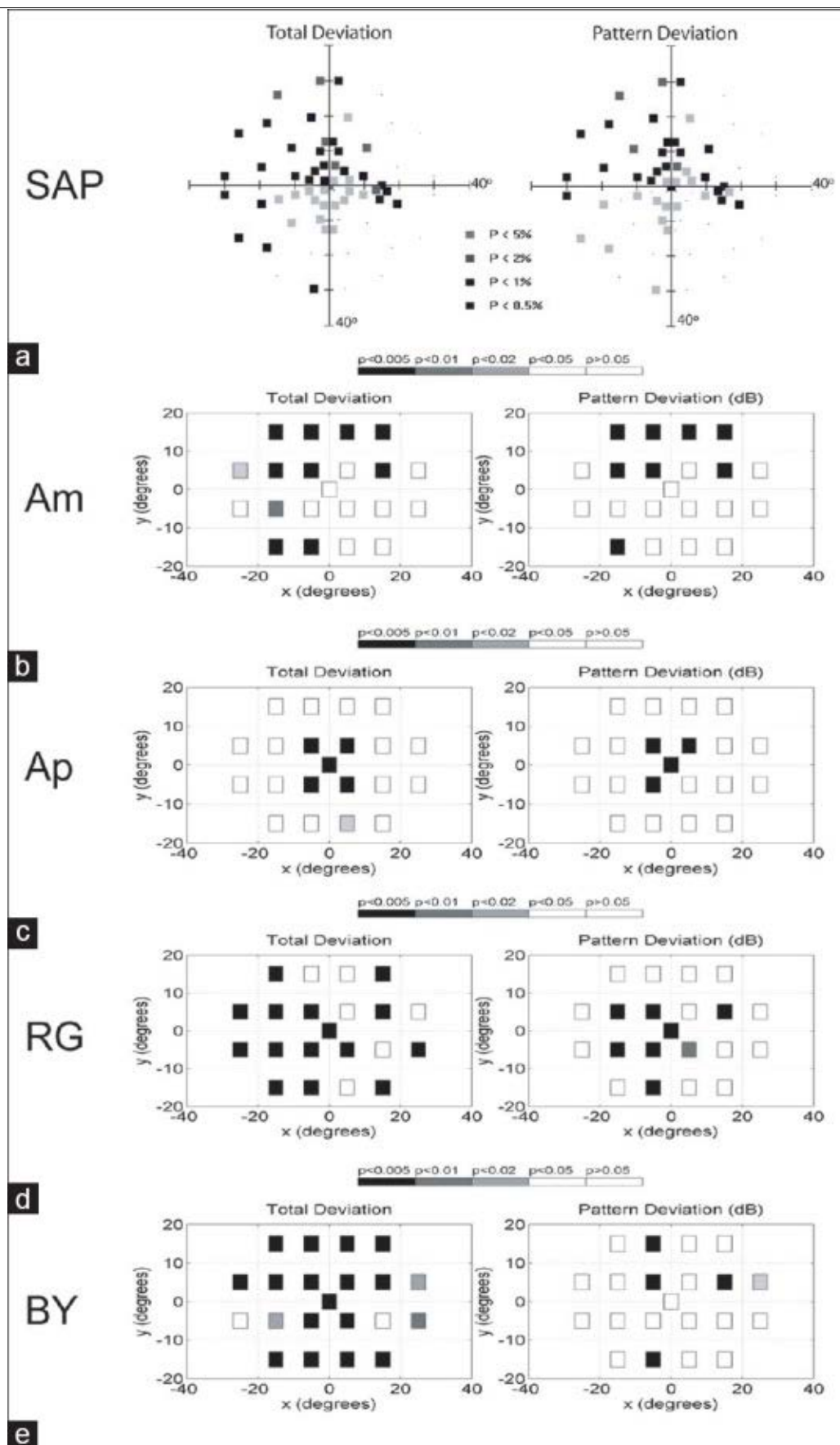
Results for patient D2, left: Total deviation map, right: Pattern deviation map. (a) static automated perimetry, (b-e) multichannel perimetry results with Am, Ap, RG and BY stimuli

Figure 4



Results for patient G1, left: Total deviation map, right: Pattern deviation map. (a) static automated perimetry, (b-e) multichannel perimetry results with Am, Ap, RG and BY stimuli

Figure 5



Results for Patient G2, left: Total deviation map, right: Pattern deviation map. (a) static automated perimetry, (b-e) multichannel perimetry results with Am, Ap, RG and BY stimuli